

Case Presentation

left buccal squamous cell carcinoma

Clerk 2 蔡翔愷 莊至桓





Basic Information

● Chart No.	
● Name	黃00
● Age	65 Y/O
● Gender	male
● Occupation	retired



Chief Complaint

left buccal ulcer for 4 months



Past History

- Acute ischemic stroke, with left proximal internal carotid artery occlusion on 2025/07/07,
- Atrial fibrillation
- Atrial flutter s/p pacemaker
- Hypertension
- Moderate tricuspid valve regurgitation, s/p mitral valve plasty and tricuspid valve plasty, s/p atrial septal defect repair



Personal history

- Social history
 - Alcohol: denied
 - Betel nuts: 20 pills/day for 20 years, quit for 1 year
 - Cigarettes: 0.5 ppd for 20 years, quit for 20 years
- Family history: denied



Review of System

General : fair

BH : 162, **BW** : 46.5

HEENT :


left buccal tumor about 4cm with
ulcer

LN : no obvious palpable neck mass

Thyroid : normal

Chest: normal expansion; normal
breathing sound

Heart: regular heart beat, no
murmur



Abdomen:

Shape : normal, Tenderness : nil

Liver : non-palpable, Spleen : non-palpable

Palpable Mass : nil

Kidney : no knocking pain Bowel

Sound : BS: normoactive

Extremities:

Extremities : no pitting edema

Pulse : normal

Present illness

- 2025/12/23 Dr.鄭 's OPD :
 - Left buccal tumor about 4cm with ulcer for 4 months, with tenderness and induration
 - pain VAS:8
 - No obvious palpible neck mass
 - Fiber: no other lesion noted in hypopahrynx/larynx, good VF motion
 - Biopsy : squamous cell carcinoma, moderately differentiated

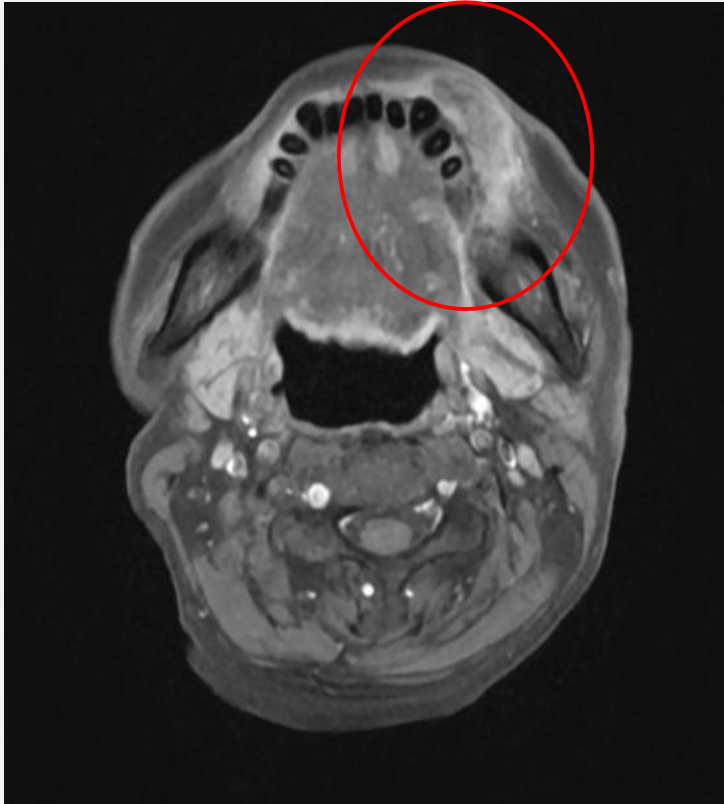


Present illness

- 2026/01/04 Admission for staging :
 - MRI : T3N0M0
 - Neck echo : no LN meta.
 - PET scan: TxN1M0, suspicious left paramandibular nodal metastasis (N1)
- Abdominal echo : Renal cyst, left
- CXR: no lung lesion noted
- PES: Reflux esophagitis and Erosive gastritis,
s/p biopsy : chronic gastritis with no Helicobacter infection

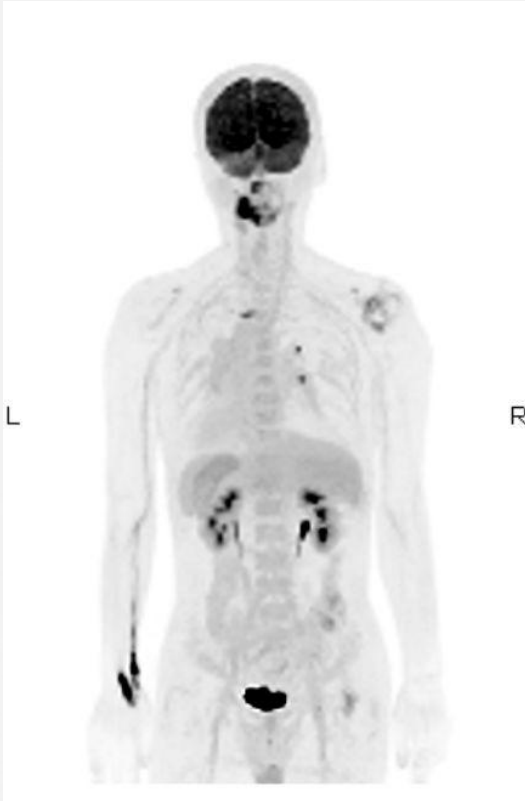

0107 MRI



- consistent with left buccal cancer
- no obvious lymphadenopathy
- T3N0M0

0106 PET




1. Viable left buccal cancer, with **suspicious left paramandibular nodal metastasis (N1)**.

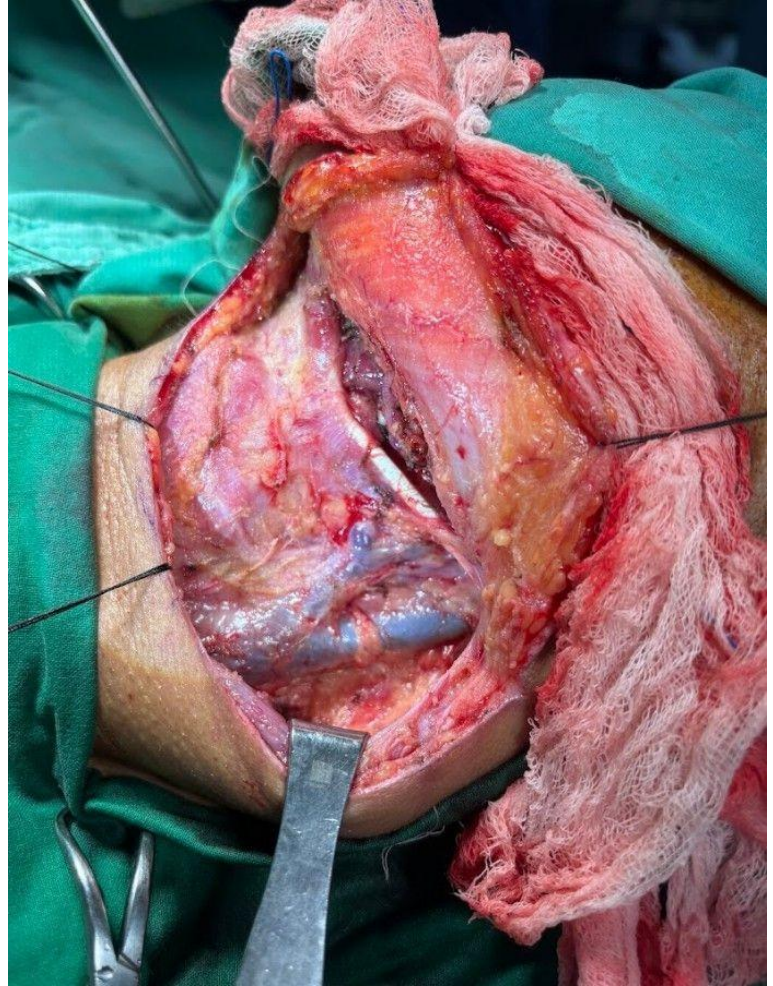
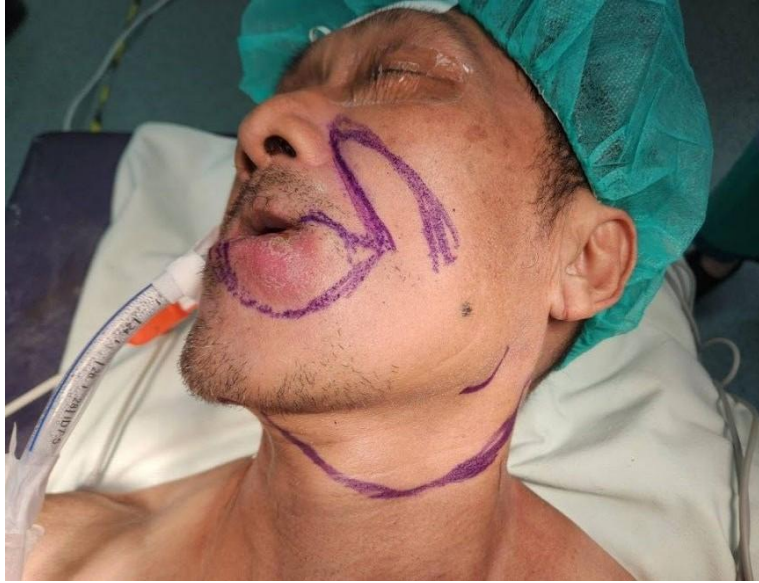2. Suspected occult malignancy at left palate, DDX: local active inflammation.

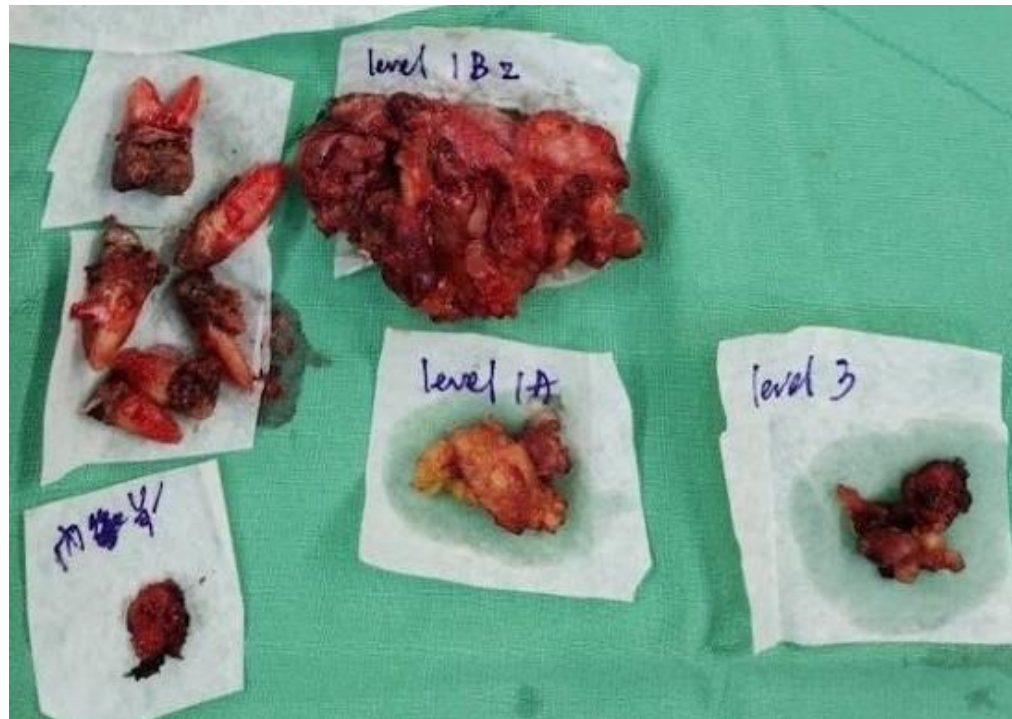
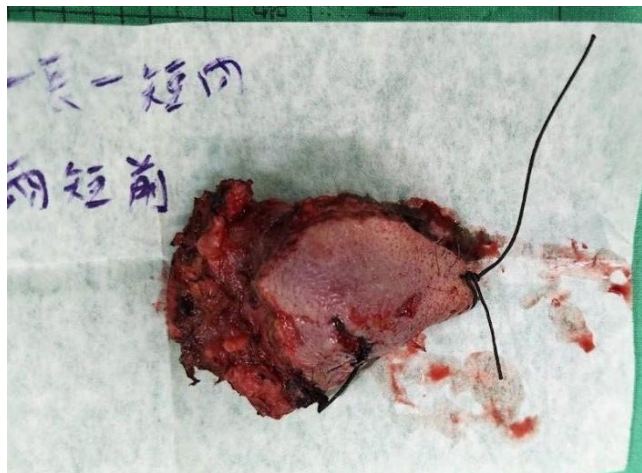
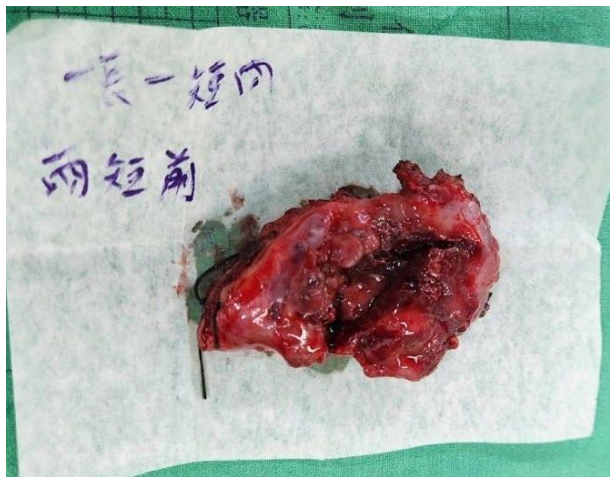

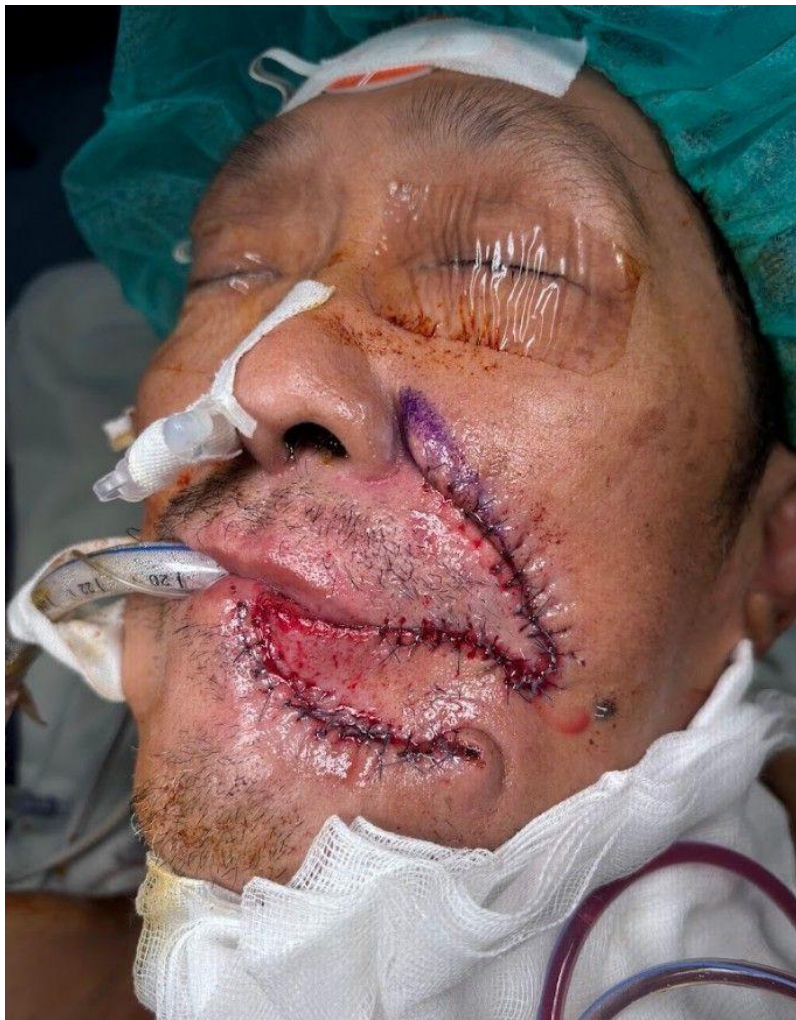
Present illness

- 
- 2026/01/20 Admission for surgery :
 - left buccal SCC, cT3N0M0, stage III
 - 2026/01/21 : left buccal ca wide excision + nasolabial fiap reconstruction + left Neck dissection level I-III + teeth extraction + NG insertion









Present illness

● 2026/01/22 Pathology pT3N0

● Impression:

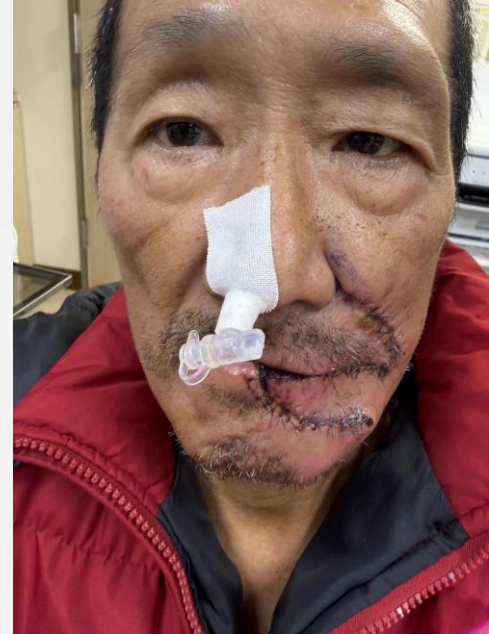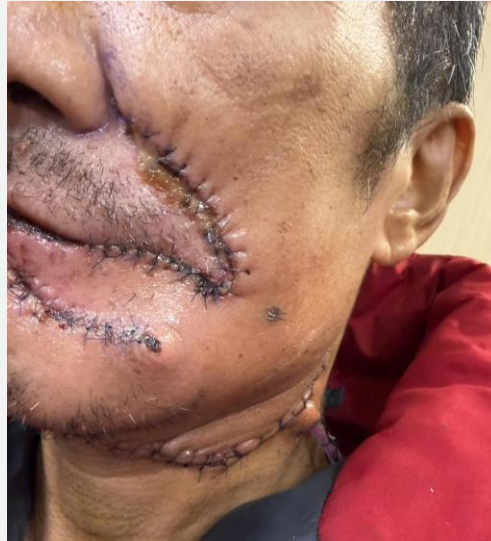1. Oral cavity, buccal mucosa, left, wide excision, Squamous cell carcinoma
2. Oral, labeled medial margin, gingival side, biopsy, no tumor involvement at one side
3. Salivary gland, submandibular, left, dissection, no tumor involvement
4. Lymph node, neck, level IA, left, dissection, **no evidence of metastasis** (0/2)
5. Lymph node, neck, level IB+II, left, dissection, **no evidence of metastasis** (0/3)
6. Lymph node, neck, level III, left, dissection, **no evidence of metastasis** (0/4)

● 2026/01/26 Discharge



Present illness

- 2026/02/02 OPD :
 - wound ok
 - refer for adjuvant RT or CCRT



Final diagnosis

- left buccal squamous cell carcinoma, cT3N0M0, stage III, status post left buccal cancer wide excision + nasolabial flap reconstruction + left Neck dissection level I-III + teeth extraction #24 25 31 32 33 34 + NG insertion on 2026-01-21, pT3N0

